

## CORRECTION OF COSMETIC PROBLEMS SECONDARY TO HAIR TRANSPLANTATION

*James E Vogel*

### INTRODUCTION

Using contemporary techniques of hair restoration surgery, the outcome is generally indistinguishable from the appearance of native scalp hair. Unfortunately, older techniques of hair transplantation usually did not produce this quality outcome. As a consequence, there are a considerable number of patients who bear the visual and psychological burden of those techniques. Regrettably, there are other patients who have similar unnatural hair transplant results from poorly performed procedures completed in recent time. Understanding the anatomic problems associated with the unnatural appearing hair transplant is fundamental to its successful correction.

The focus of this chapter is to provide a useful review of the most common cosmetic problems the hair transplant surgeon is likely to encounter. A practical approach to managing these cosmetic deformities has been a particular interest to the author (1–3) and the most recent refinements are presented. The most frequent type of cosmetic problems following hair transplants are as follows:

1. Unightly appearance of plugs
2. Wide scars in the donor area
3. A poorly designed hairline
4. Surgical distribution of grafts that failed to consider the progressive nature of hair loss in a young patient.

### Unightly Appearance of Plugs

The fundamental problem with the unnatural appearing hair graft is the size of the graft. Thus, the fundamental solution is simply to reduce or remove it. The concept of grafting alone anterior to the pluggy hairline to achieve softening is misguided and does not address the basic plug problem (Fig. 17-1). The first person to describe an effective approach to the fundamental problem was Lucas (4). This original description was to partially excise the plugs using a 1.5- to 1.7-mm punch biopsy instrument. Our current technique (2–4) is to employ a punch that is approximately 0.5 to 0.75 mm smaller than the estimated size of the unsightly plug or clumped graft. Thus, if 4-mm plugs are being addressed, a 3.5- to 3.25-mm punch would typically be chosen for plug reduction. The reason for this is to remove a substantial amount of the plug hairs and leave behind a few hairs that will look soft and natural.

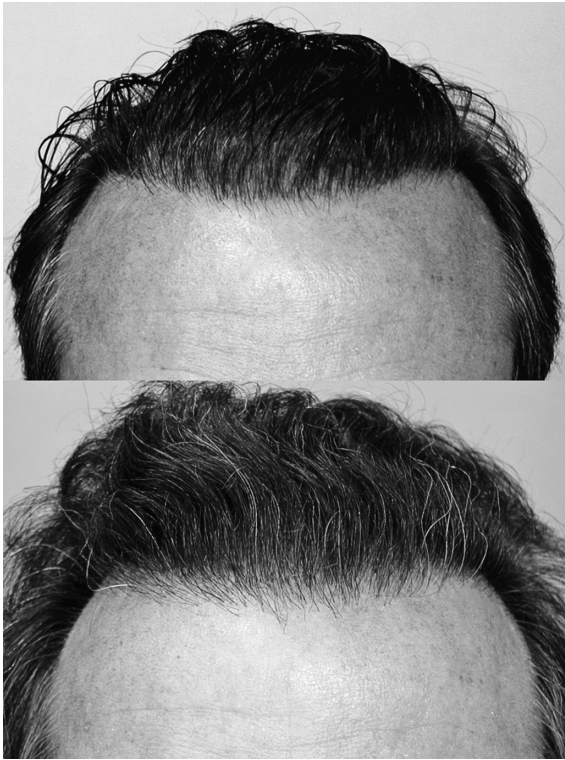The actual technique of plug removal is very straightforward. The hair in the plugs to be reduced are trimmed to approximately 3 mm length and the punch positioning for hair removal is performed eccentrically to leave a crescent or sliver of the remaining original plug. This effectively leaves behind

a linear graft of approximately 3 to 4 hairs. When doing this, it is important to angle the punch parallel to the follicles. Reducing the number of transected hairs in the excised section maximizes the recycling yield of healthy usable follicular units (FUs) within it. Unfortunately, a considerable degree of scar tissue often surrounds and distorts the deep architecture of the plugs being removed. This scar tissue increases the transection rate during the excision. In general, a yield of 50% to 80% would be expected. Care should be taken to pass the punch instrument deep enough to include 1 to 2 mm of subpapillary fat (Fig. 17-2). Including the entire papilla and its underlying fat accomplishes two goals. First, removal of the entire portion of plug to be excised increases the likelihood permanent plug reduction. Second, sufficient fat below the intact hair follicle helps to maintain viability of the FU as they are trimmed and recycled. The use of sharp excision punches and frequent exchange of a punch when it becomes dull is also an important technical point to minimize shearing and damage to the peripheral plug follicles.

A partial or timid approach to the plug removal will be reflected in the result. Our concept is to be as aggressive as possible with removing plugs so as to obtain the best improvement in a single procedure (Fig. 17-3). Care must be taken however to assess the local blood supply in the face of a previously scarred scalp and always limit plug reduction and subsequent grafting in the immediate area to an appropriate degree based on clinical judgment and local tissue perfusion.

The hair recycled from the removed plugs, as well as additional hair concomitantly harvested from the occipital region, is densely transplanted anterior, posterior, and most importantly adjacent to the plug reduction sites. In the majority of cases, the plug reduction sites are not sutured closed. This represents a change from the authors earlier reported technique (2,3). Suturing the sites reduces the local blood flow and increases scalp tension, thereby reducing the success of graft growth in the vicinity of the plug reduction sites. This last caveat is important because new hair growth next to the reduced plug is the precise location where we want to maximize new coverage. If grafting is not performed in areas of plug reduction, suturing of the site with an absorbable suture (i.e., chromic) is always performed. Clearly suturing the sites does make general wound care easier for the patient in the first few days of healing and immediately postoperatively. It is to be emphasized that fortunately the final appearance of the healed scar following plug reduction is essentially indistinguishable whether the site was sutured or left to heal by secondary intention.

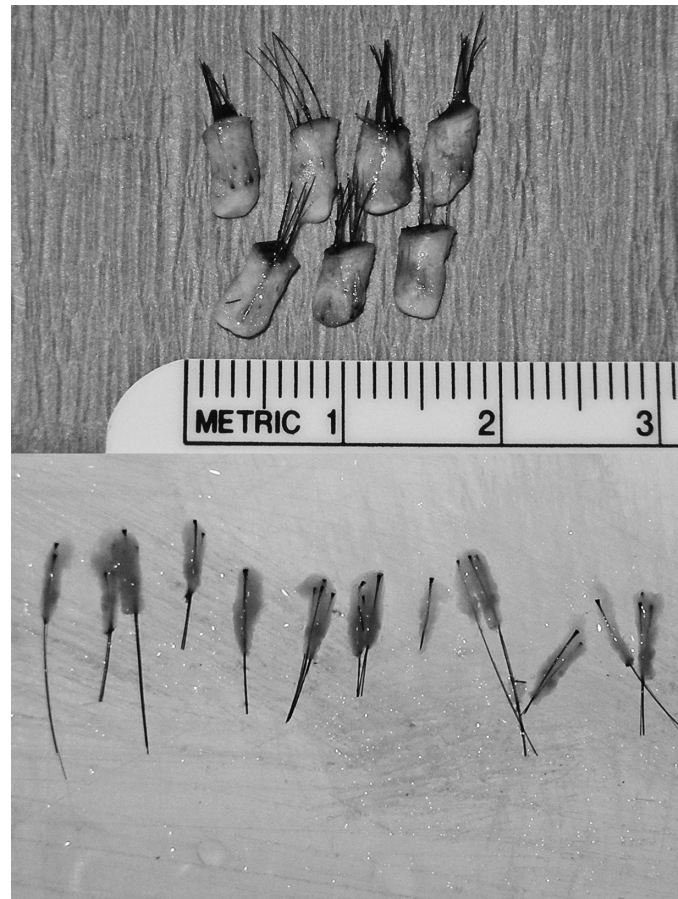Usually, there are several wide tracks of alopecia that exist between the linear rows of plugs, which need to be



**Figure 17-1** Inadequate correction of the pluggy hairline. Results from another practice showing failure of FU grafts alone to camouflage the “cornrow” or pluggy appearance of a previous hair transplant. As seen following a single procedure, an aggressive removal of the plugs themselves along with grafting needs to be incorporated into the plan to create a more natural hairline. *Source:* From Ref. 3.

densely transplanted. Plugs that exist more than 2.5 to 3cm posterior to the anterior hairline can often be left intact. Aggressive management of the first two or three rows of plugs as described is usually all that is necessary to soften and naturalize the hairline and camouflage the more posteriorly positioned plugs (Fig. 17-4). This approach blends the soft look of the anterior hairline zone with the higher hair density of the plugs posteriorly. In many cases, the posterior row of plugs is also reduced in the crown and additional grafting is needed in the vertex to create a natural “posterior hairline” as well. While each patient’s distribution of problem plugs is unique, the final surgical plan is to create a zone of natural appearing hair at the leading edges, anteriorly as well as posteriorly and taking advantage of the centrally located higher hair density plugs. In some situations, however, the patient may prefer to soften all plugs previously grafted.

Two and sometimes three sessions of plug reduction are usually needed to adequately convert the hair transplant appearance from unnatural to “natural enough” for most patients’ satisfaction. In general, we prefer to wait for eight months following the first corrective transplant to assess the results and proceed to the next staged repair. Sometimes a “faster track” approach can be employed and additional plug reduction and grafting can be performed with in a shorter time interval (Fig. 17-4). The advantage of the “faster track”

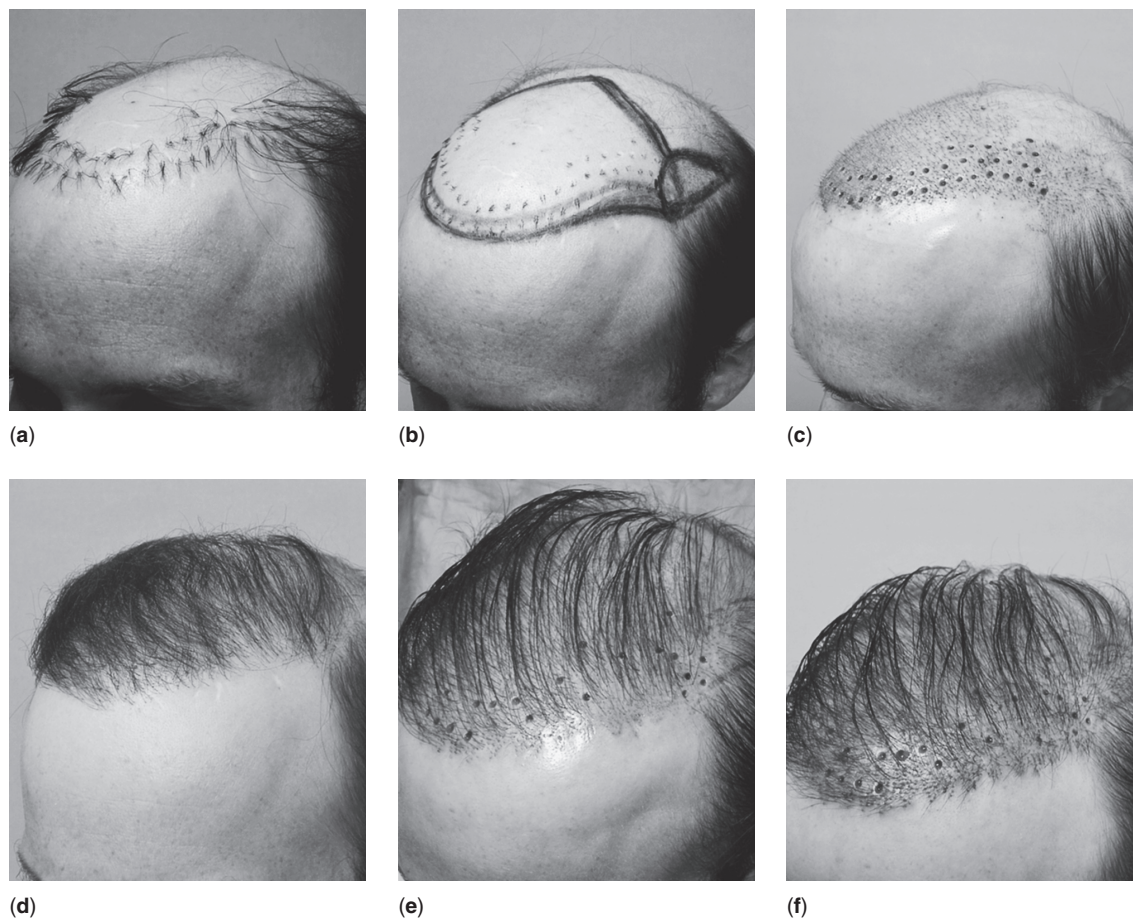


**Figure 17-2** Removed and recycled grafts. The appearance of 3.5mm plugs removed from a patient who had previous 4mm plugs grafted at an earlier age. A smaller punch is chosen to leave behind a few hairs that will look soft and natural. These plugs are microscopically dissected to salvage and recycle.

is, of course, a sooner completed result. The disadvantage is not having a complete picture of the healed first stage to formulate the second stage plan.

Another option to plug reduction is direct linear excision of the anterior hairline plugs (Fig. 17-5). This has several advantages. These include an aggressive direct attack on the offensive appearing plugs, a ready supply of hair that can be recycled into FU with minimal follicle transection, elevation of the hairline that is usually too low, avoidance of having to primarily rely on an already scarce supply of hair in a typically tight and depleted donor area. Recycled hair can be safely grafted anterior to the sutured hairline closure. The advantage of grafting at this location at the time of initial surgery is to provide the first of two needed transplants anterior to the softened plugs. An untransplanted alopecic gap of no hair growth between the sutured hairline and the first pass grafts is to be expected and will need supplementation during a second session. Direct linear excision of the anterior hairline is also a technique for correction of blunted temporal points (Fig. 17-6).

Regardless of the timing between surgeries or the specific technique for addressing the pluggy appearance, the



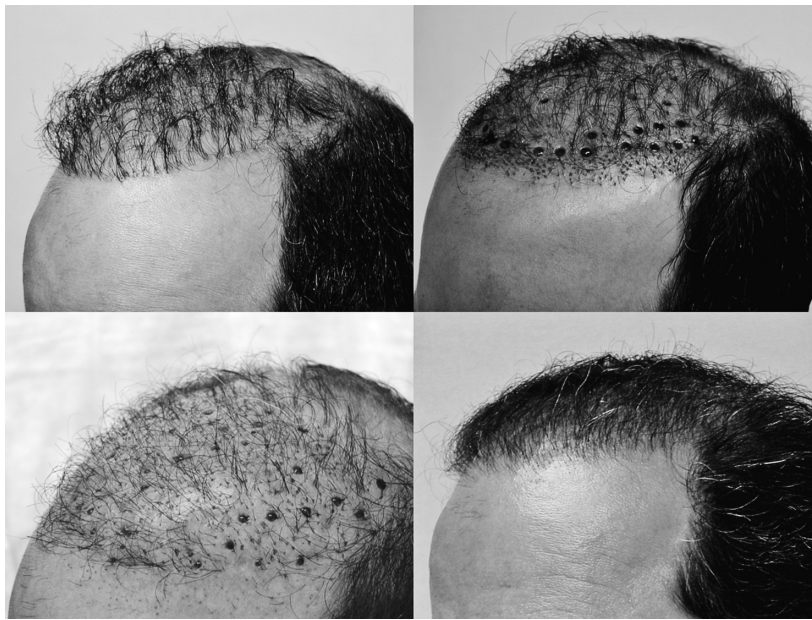**Figure 17-3** Technique of plug reduction and recycling (PR &R). (a) This man had previously undergone a hair transplant using 4 mm plugs at an early age. Progressive hair loss has worsened the appearance requiring the patient to wear a hair piece. At one point, he had a sewed in toupee and those permanent scars are seen at the hairline. (b) Preoperative planning to re-create a forelock and elevate the temporal fringe. (c) Intraoperative appearance of aggressive plug reduction, recycling of plug grafts (PR&R), and adding 1500FU. Note the open plug reduction sites and grafting immediately adjacent to them. (d) Results at 8 months. Significant improvement can be obtained using the technique described in the first session. (e) Intraoperative appearance, before grafts are planted. (f) Immediate postoperative appearance during second surgical session to thicken forelock and lower hairline. Note the less aggressive plug reduction needed at the second stage. About 1200 grafts were planted during the second session.

importance of preoperative discussion and a review of realistic goals and expectations with the patient before undertaking a corrective transplant cannot be overstated. Establishment of mutual trust, an appreciation for anticipated progressive hair loss and improvement from plug reduction are essential to achieving a successful outcome. In addition, the nature of residual scarring from previous hair transplants and the ability of the newly transplanted hair to camouflage open spaces and any remaining plugs must be thoroughly reviewed and appreciated by the patient preoperatively.

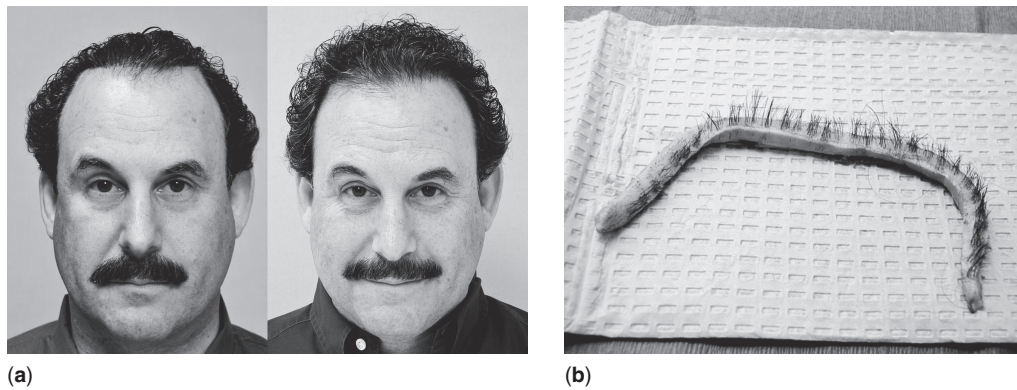
### Wide Donor Area Scars

Donor site scarring occurs following all techniques in which hair is obtained for transplantation. The scars can range from imperceptible to extremely deforming. Today, the most common donor site problem seen in practice is a donor scar approximately 1 cm or more wide that occurs as a result of multiple harvests in a single site or over resection during a single session. The common denominator in both scenarios is excessive tension on the donor wound closure.

In the past, the author has used a W-plasty scar revision and other approaches utilizing local tissue rearrangement and mobilization (1,2). Unfortunately, these approaches have usually fallen short of the desired goal. It does not make sense that removal of additional scalp and retightening of an already tissue-deficient area will solve the problem of scar widening. In very rare occasions, if sufficient and unusually lax occipital scalp is present, direct excision of the widened scar with layered or trichophytic closure can be performed. This situation is the exception and not the rule. Logic and sound surgical principles dictate that tissue expansion with flap advancement or hair grafting into the wide donor scar are the two best options for managing the wide donor scar (Fig. 17-7). If an individual is interested in shaving his scalp hair and has one or a limited number of donor scars he wishes to camouflage, follicular unit extraction (FUE) with grafts removed from the scalp or body transplanted into the scar is another option (chap. 9G). The advantage of body hair as a donor is avoidance of another scalp donor site scar and the creation of stubble to help disguise the donor scar.

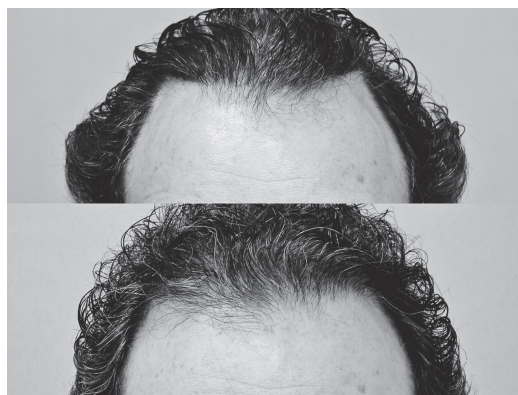

**Figure 17-4** Fast-track plug reduction and recycling. Upper left is pre-op, upper right following 45 plug reductions and 1500 FU grafts, lower left is six weeks later and an additional 40 plug reductions and 1000 FU grafts, lower right is nine months following the initial procedure. *Source:* From Ref. 3.



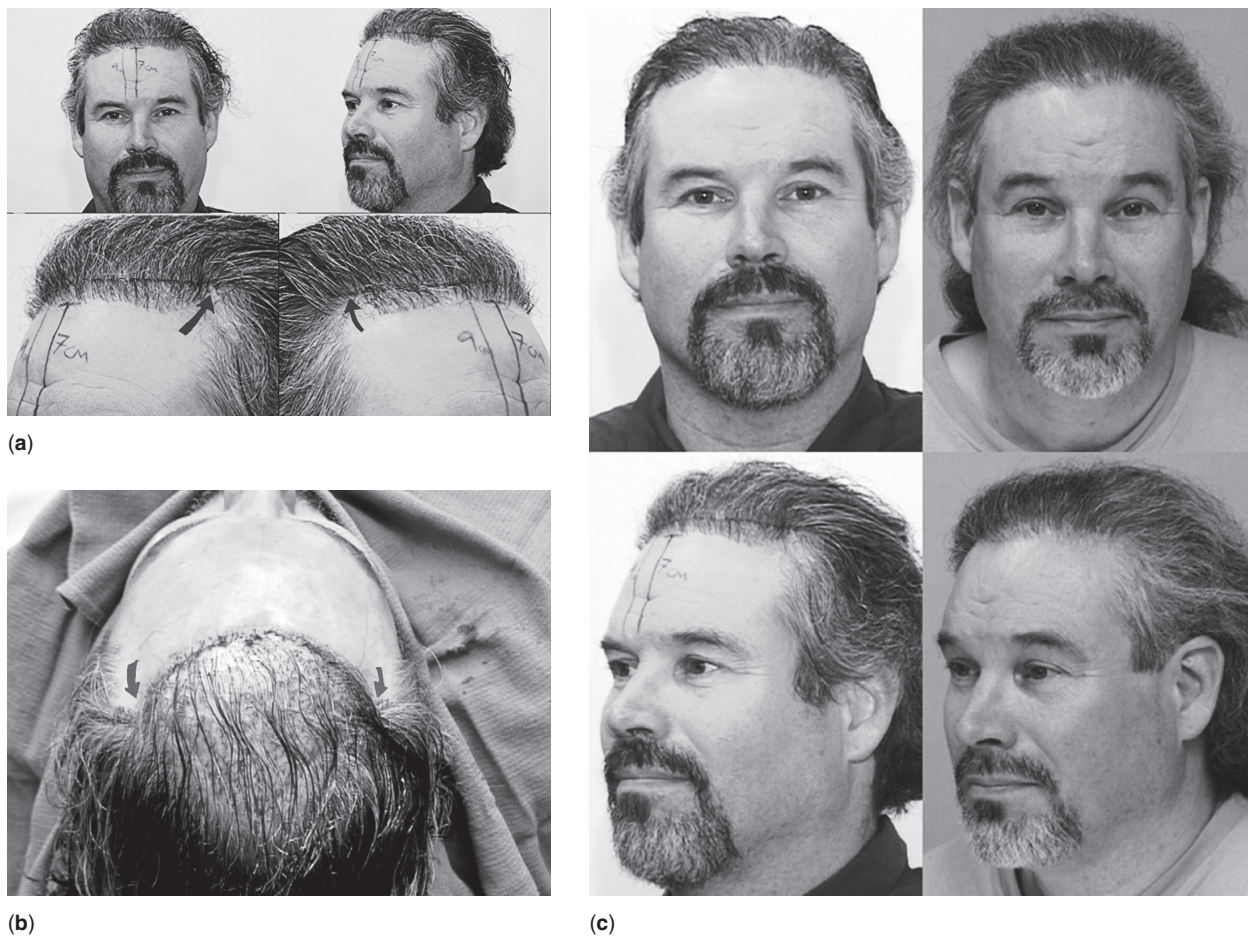
(a)

(b)

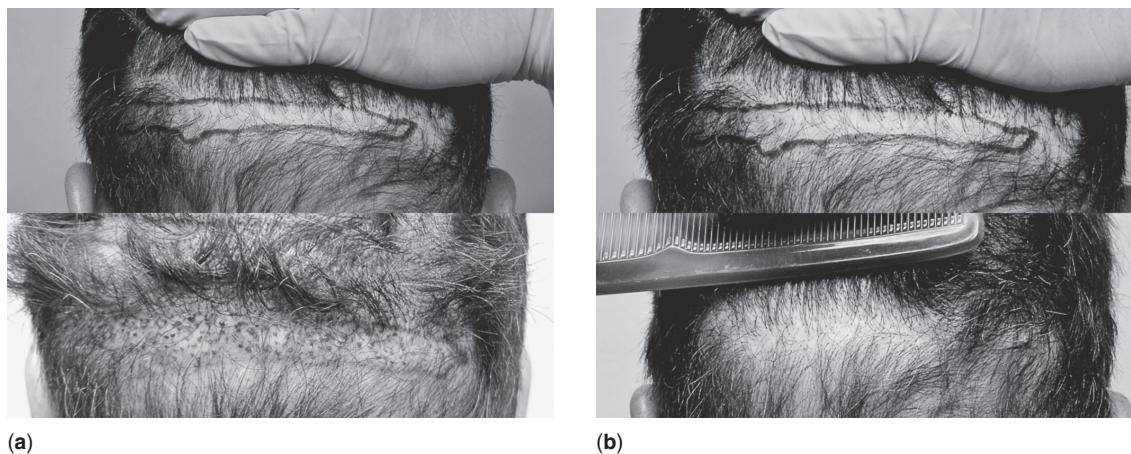


(c)

**Figure 17-5** Linear excision of pluggy hairline and recycling. (a) Case illustrating the use of linear excision of the anterior hairline to remove the pluggy grafts. (b) Intraoperative appearance of the excised pluggy anterior hairline. (c) Final close-up results following a second session of limited plug reductions and 1500 grafts. Even though the patient had two corrective operative sessions, the occipital donor area was used only one time.



**Figure 17-6** Correction of poorly designed hairline. (a) Abnormal hairline due to grafts placed too low with blunting of temporal recession. Blue dashes indicate location of incision for elevation of hairline and arrows specify the angle of hairline rotation to re-create acceptable temporal points. (b) Intraoperative view with recycled grafts in place. (c) Postoperative results at one year following the initial depicted procedure and a subsequent transplant session with a total of 2200 grafts. *Source:* From Ref. 3.

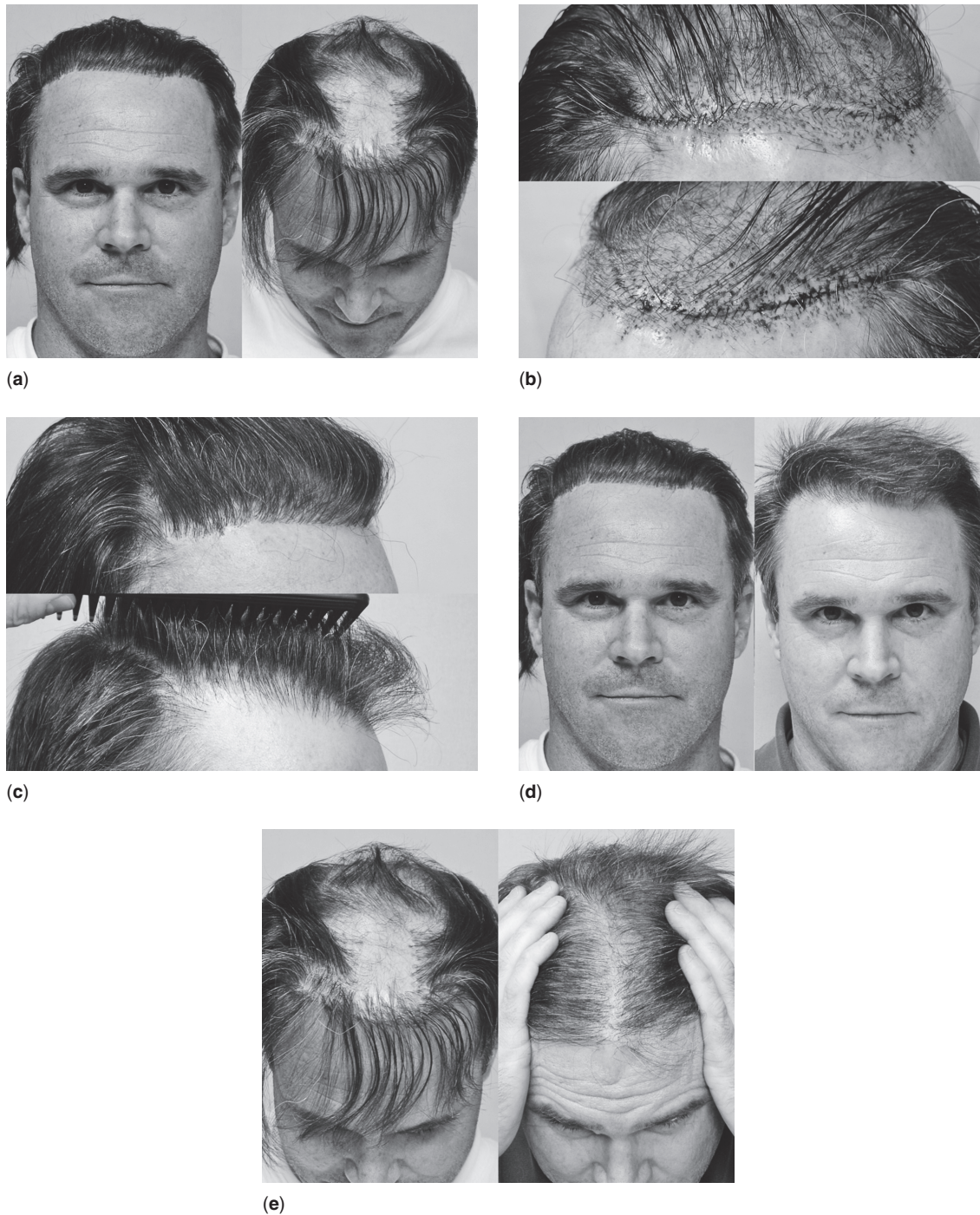


**Figure 17-7** Correction of wide donor scar. (a) Wide donor scar and single session of 250 FU grafts. (b) Results at 8 months. *Source:* From Ref. 3.

### Poorly Designed Hairline

Common hairline design problems include blunting of the temporal angles, lack of symmetry, and a hairline that is positioned too low on the forehead. Surgical excision, redesign, and elevation of the hairline are usually necessary to

correct these problems. In most cases, the hairline can be redesigned in a single surgical session and hair grafts can be concomitantly incorporated into the surgical plan as part of a comprehensive approach to correction (Fig. 17-8). However, as stated above with regard to plug correction, a second and



**Figure 17-8** Correction of unnatural hairline and problems due to progressive hair loss. (a) A 42-year-old who underwent right temporal–parietal scalp flap at age 22. His hairline is too low, the temporal angles are blunted, the direction of hair growth is unnatural, and visible plugs are evident behind the flap as well as conspicuous progressive hair loss posterior to the flap. (b) The flap is excised and recycled into approximately 1400FU, which are immediately used for hairline restoration anterior and posterior to the flap excision suture line. No additional occipital donor harvest performed. (c–e) Results following second session performed 8 months later consisting of residual plug reduction and recycling and occipital harvest for 1800FU session. Note the improved bilateral temporal recession. *Source:* From Ref. 3.

not infrequent third hair transplant session is often necessary to complete the correction of the poorly designed hairline (Fig. 17-6).

### Progressive Nature of Hair Loss

Supply and demand is a central theme in many aspects of our lives and is very critical to understanding what can and cannot be achieved regarding surface coverage of the scalp. A variety of unattractive and peculiar appearances have resulted years following the performance of a transplant in an individual who has undergone progressive hair loss following the initial hair restoration procedure (Figs. 17-2, 17-4, 17-5, 17-6, and 17-8). The appearance of these patients illustrates the devastating outcome that can occur when there is disregard and inattention to the progressive nature of hair loss. Establishing a hair transplant plan for the young patient that is conservative and does not commit more donor supply to an ever enlarging area of demand (i.e., progressive hair loss) is essential to avoid these problems. A combination of plug reductions, linear excision, conservative grafting, and adjunctive medical therapy (e.g., finasteride) to reduce ongoing hair loss are the key factors to treat the illustrated deformities.

### CONCLUSION

Other reports have outlined options for management of the unnatural appearing hair transplant (5–9). This chapter represents the author's current refinement of earlier published articles on the same topic (1–3). The challenge for the hair restoration surgeon is to provide a level of expertise and honesty to these unfortunate patients to restore their appearance and self-confidence. When the surgeon is faced with correcting these types of problems, creativity, long-range surgical planning, and a variety of techniques described above are employed. The exact techniques used in an individual patient will be as varied as the presenting problem itself. Fortunately, many patients with unsightly hair transplants can expect anywhere from cosmetically significant to tremendous improvements, if revisions are planned and carried out appropriately.

## 17A. COMMENTARY

Walter P Unger

Space limitations in this edition of *Hair Transplantation* have necessitated a shorter than ideal discussion on the subject of this chapter. Fortunately, longer and excellent ones have been presented previously by Rassman and Bernstein (1) and by this commentator in the last edition of *Hair Transplantation* (2). Readers who need or want something more complete can refer to one or both of them. Fortunately, nothing has changed very much since they were published except that once again there is virtually no need for multi-FU grafts anymore. (In any case, if such grafts were advantageous, few surgical teams would know how to use them now.) Despite the preceding, a few subjects should be elaborated on or added to Vogel's presentation.

1. The excision of some areas of a badly performed hair transplant can sometimes be useful. Such an approach can offer a way of removing unanticipated alopecic areas that have developed since the initial transplanting without instead utilizing the limited number of FUs available from any still

usable donor area. Those FUs can then be employed to better effect in previously transplanted areas as described by Vogel. Some areas that have been transplanted previously but without sufficient hair density can also be excised and any grafts within them recycled to other transplanted sites. In other words, alopecia reductions (AR) have not outlived their usefulness and therefore should not be forgotten. AR should ideally be carried out concomitant with or prior to grafting so any scar from an AR can have hairs transplanted into it if that should be deemed necessary.

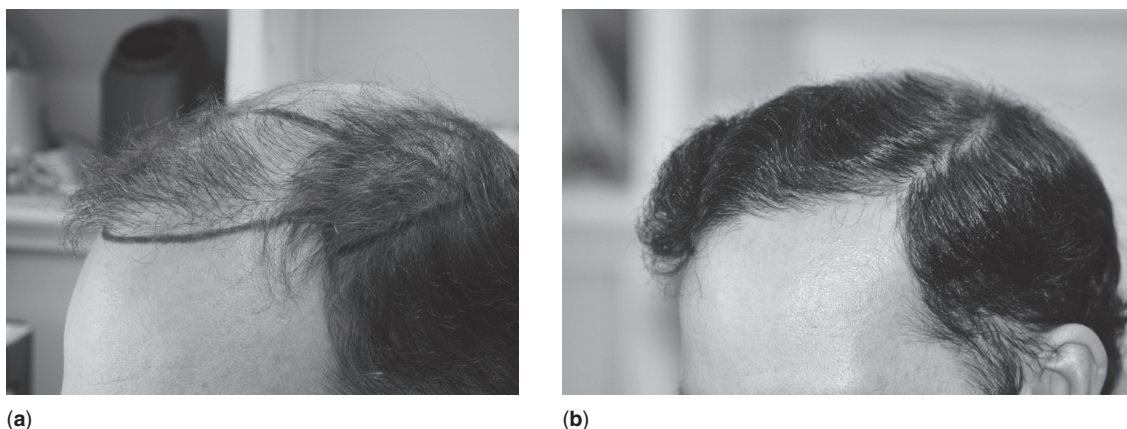
2. We are currently seeing far more poorly carried out or planned FUT than 7 years ago when the last edition of this text was published.

In the recipient area, the most frequent problem is insufficient hair density. That can usually be easily addressed by further hair transplanting. However, not far behind the frequency of that problem is the failure to anticipate or promptly transplant areas of evolving MPB that were not transplanted at the time of the initial treatment. The patients we see are often most unhappy with the fact that they were not advised that this would be necessary and usually cannot be persuaded to return to their original hair restoration surgeons instead of coming to us because they have lost trust in them. An almost as frequent problem, that is often associated with the others, is that the FUs that were transplanted earlier were not properly sorted as to the numbers of hairs in each FU, hair textures and sometimes hair coloring as it relates to their location in the recipient area. In particular, FUs should ideally be segregated at the time of their preparation into groups that contain fine-textured 1, 2, and 3 or more hair FUs and those that contain coarser 1, 2, and 3 or more hair FUs (see also chaps. 10F and 12F1). At the time of graft implantation, technicians can then easily insert the ideal grafts for each area. Correction of the above two problems is demonstrated in Figure 17A-1 and basically consists of transplanting the new areas (if sufficient donor reserves are available) and surrounding grafts containing coarse hair with finer textured ones or, less frequently, excising them.

3. For patients as well as doctors, noticeable and unsightly donor area scars are the most feared consequence of modern hair transplanting. Broadly speaking, they take two forms, (i) a single wide scar or (ii) multiple scars, some of which may or may not also be too wide, (though usually they are). The latter is sometimes referred to as "railroad" or "ladder" scarring and is usually further complicated by sparse hair between them, making them even more noticeable.

### A SINGLE WIDE SCAR

The subject has already been briefly dealt with in my commentary for chapter 9A2 but I will elaborate on it here. A wide scar is usually the result of too much wound tension at the time of closing or *several days later when donor area edema is maximized*. When revising such scars, the primary focus should be to avoid this happening again. Improvement can nearly always be accomplished if the excision width is properly chosen. In this commentator's experience, it ideally should be narrow enough that when the wound is closed the surgeon feels the width could have been 2 or 3 mm wider; this allows for the tension that will develop over the following few days as edema in the area increases. It also usually means that the scar needs to be removed sequentially in multiple stages rather



**Figure 17A-1** (a) This 39-year-old patient had a “FUT” procedure carried out by another physician 3 years before this photograph was taken. A number of errors had been made. These included a failure to transplant into evolving areas of hair loss, and the placement of grafts that contained too many hairs, of too coarse a texture, in the hairline zone. The black crayon outlines the area that we proposed to treat. (b) The patient returned 9 months after his first repair consisting of 1973 FUs. A new hairline had been created using finely textured 1- and 2-haired grafts. The rest of the frontal area was repaired by surrounding prior grafts with FUs, and by extending the transplant into adjacent areas of evolving hair loss. A third session, this time to the midscalp, was carried out 2 months after this photo was taken.

than trying to excise all of it. Scars also generally have different widths at different points along their length. It is best to remember that where the scar is widest, this most often occurred because of originally unanticipated tension vectors on the first occasion (unless there is a history of wound infection). It is likely that such “unexpected” vectors still exist and in fact almost certainly are worse because of deep wide and tethering adjacent scar tissue. (In addition, permanent vascular damage may complicate healing.) You are in fact being visually warned by past history to excise narrower widths where the scar is widest rather than the reverse—which unfortunately is the inclination of most surgeons who are revising a scar.

There are three other ways to minimize wound tension:

1. Massage the donor area to improve scalp laxity before the scar revision, as described by Wong in chapter 12D and shown in the accompanying Video 12D of that section.
2. Use corticosteroids—both orally and intralesionally inferior to the closed wound, immediately after completing the closure. Unless there are contraindications we recommend 60mg of oral prednisone 1 hour before surgery and the following morning, followed by a “dose pack” beginning with 30mg and tapered daily by 5mg per day over one week. We also infiltrate a total of 5 to 6 ml of a 3.33mg/ml solution of triamcinolone acetonide (Kenalog)—10mg/ml diluted with bupivacaine (Marcaine) 0.5%—just inferior to the wound; 0.2ml is injected at each injection site. (The bupivacaine prolongs the initial anesthetic field block.)
3. Excise the donor wound scar tissue that is deep as well as lateral to the strip excision. Also, undermine the superior flap or both the superior and inferior flap if, when you try to approximate the wound edges prior to closing, you discover more tension than you anticipated. This is demonstrated (see Video 9A3.1) in the accompanying DVD and discussed in chapter 9A3. If you still encounter too much tension on closure consider a two-layer closure and/or use

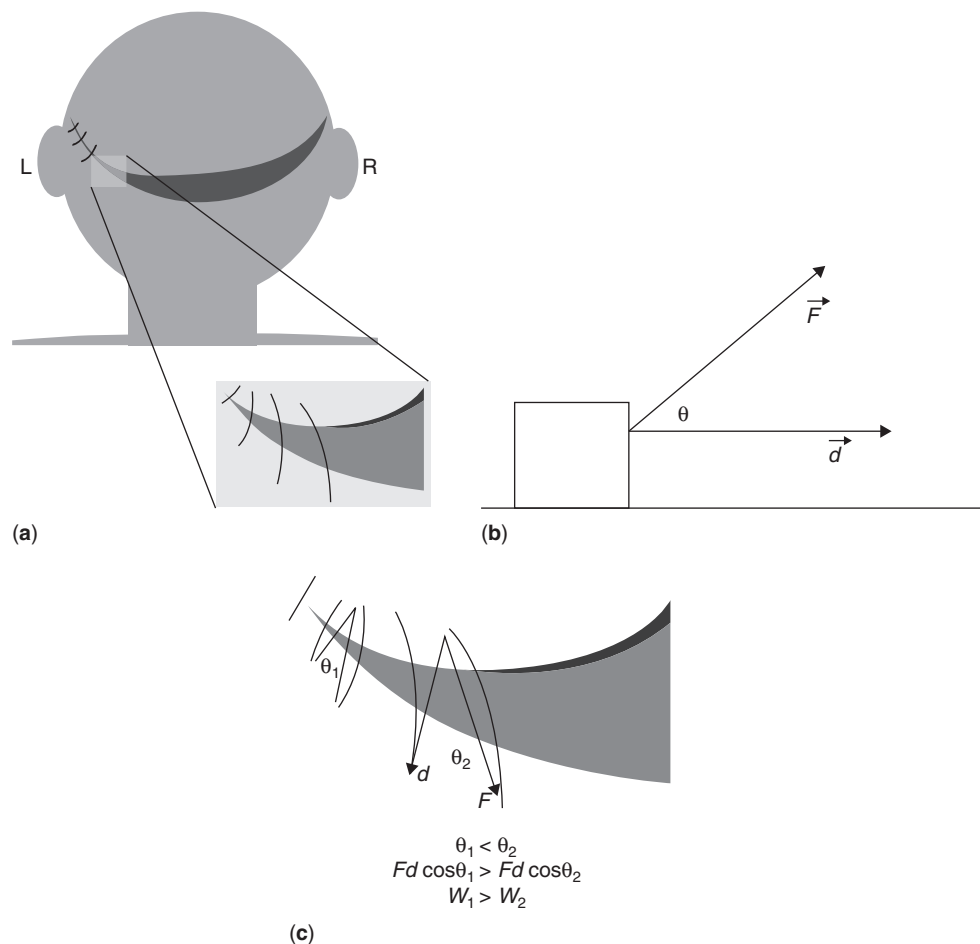
either staples or interrupted sutures instead of running sutures. The latter will impair blood supply to the wound more than staples or interrupted sutures. Interrupted sutures should be inserted obliquely to each other in areas of maximum tension because this can reduce the closing tension remarkably at those sites (Fig. 17A-2). There is a mathematical explanation for this phenomenon (3). With regard to blood supply, one edge of the excised strip should ideally always run through intact skin instead of both edges running through scar. Preferably the intact edge should be the inferior one, which will usually provide the best blood flow.

### “RAILROAD” OR “LADDER” SCARS

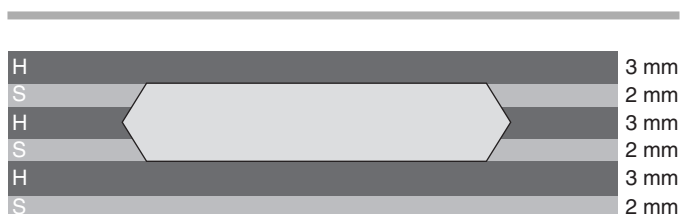Ideally one should start with the most inferior one. The blood supply is coming from a “virgin” area inferior to the wound and postoperative edema can drain away without its impediment by scar(s) inferior to it. Sometimes, however it is more cosmetically urgent to excise the widest scar first. If there are scars inferior and superior to a scar you are attempting to excise, be extra cautious with your excision width and closing tension. Blood supply and tethering of *both* wound edges by adjacent scar tissue will be particularly counterproductive; wounds in such locations are more susceptible to infection and wound dehiscence when the sutures or staples are removed. Because of the latter we will usually leave them in place for 2 or 3 days longer than usual—for example 10 to 12 days.

It is also important to remember that any hair-bearing skin between an old scar and the new wound will have its blood supply compromised from both sides and will therefore be more susceptible than usual to infection or necrosis. In addition, the hair density in that hair-bearing section will be decreased as the skin is stretched by the closing. For both reasons, you must be careful to not leave too narrow a zone of hair between the old scar and what will be a new and hopefully narrower scar.





**Figure 17A-2** (a) The mastoid region, where scalp tension is often greatest, is the zone in which a wedge suture may be advantageous. A magnified panel illustrating how the placement of wedge sutures is slightly wider along the inferior edge of the donor area. (b) A block is pulled by a force ( $F$ ) at an angle ( $\theta$ ) to a horizontal vector ( $d$ ). The work ( $W$ ) required to pull the block along the horizontal plane ( $W = Fd \cos \theta$ ) is reduced as  $\theta$  increases. (c) The work of a suture to bring two wound edges together is minimized as the placement of sutures along the inferior donor edge widens, thus increasing the angle ( $\theta$ ) along the superior edge (3).



**Figure 17A-3** The shaded area represents zones excised from a previously harvested donor area consisting of alternating bands of hair (H) and scar (S). Note: (i) As much or more scar tissue is excised than hair-bearing tissue. (ii) Two hair-bearing strips are left adjacent to each other after the excision. The result is that the hair will appear to be denser in that general area, despite the removal of additional hair from it.

Notwithstanding the preceding, the ultimate goal is to ideally turn two scars into one scar whenever that is possible. Interestingly, improvement of scars secondary to the old punch harvesting technique is usually far easier to accomplish

than the wide “ladder” scars of strip harvesting (Fig. 17A-3). Not only does the conversion of two scars into one result in fewer scars in the donor area but it also avoids vascular or hair density problems in the hair-bearing strip between a scar and a new excision and provides some hair for transplanting. The grafts produced from the latter can either be used in the other donor area scars or the recipient area.

## REFERENCES

### Correction of Cosmetic Problems Secondary to Hair Transplantation

1. Vogel JE. Correction of the cornrow hair transplant and other common problems in surgical hair restoration. *Plast Reconstr Surg* 2000; 105: 4.
2. Vogel JE. Correcting problems in hair restoration surgery: an update. *Facial Plast Surg Clin N Am* 2004; 12: 263–78.
3. Vogel JE. Hair restoration complications: an approach to the unnatural appearing hair transplant. *Facial Plast Surg* 2008; 24: 453–61.
4. Lucas MWG. Partial retransplantation: a new approach in hair transplantation. *J Dermatol Surg Oncol* 1994; 20: 511.

5. Unger WP, Shapiro R, eds. Hair Transplantation, 4th edn. New York: Marcel Dekker, 2004: 375.
6. Brandy DA. Techniques for the refinement of abrupt hairlines and donor scars secondary to obsolete punch hair grafting and flaps. *Am J Cos Surg* 1995; 12: 4.
7. Epstein J. Revision surgical hair restoration: repair of undesirable results. *Plast Reconstr Surg* 1999; 104: 1.
8. Bernstein RM. The art of repair in surgical hair restoration—part II: the tactics of repair. *Dermatol Surg* 2002; 28: 10.
9. Brandy D. Corrective hair restoration techniques for the aesthetic problems of temperoparietal flaps. *Dermatol Surg* 2003; 29: 3.

### Commentary

1. Bernstein R, Rassman W, Rashid N, Ascione S, Shiell R. The art of repair in surgical hair restoration. *Dermatol Surg* 2002; 28(10): 873–93.
2. Unger WP. Correction of cosmetic problems in hair transplantation. In: Unger WP, Shapiro R, eds. Hair Transplantation, 4th edn. New York: Marcel Dekker, 2004: 372–9.
3. Unger RH, Wesley CK. Technical insights from a former hair restoration surgery technician. *Dermatol Surg* 2010; 36(5): 679–82.